

## Cost-effectiveness of Bilateral Orchidectomy in the Treatment of Advanced Prostate Cancer

\*Udoh EA, Akaiso OE, Ukpung AE, Essiet IU

### ABSTRACT

*Prostate Cancer has been known to be the commonest malignancy of the male urogenital tract. It usually affects elderly and middle aged men. Hormonal manipulation is usually indicated as treatment option in locally advanced and metastatic diseases. In a developing economy such as Nigeria, the cost of treatment of diseases is usually a big issue. This is more so with the treatment of prostate cancer. The lower cost and increased convenience, with fewer side effects, makes bilateral orchidectomy a superior option. In this article, we compared the cost of bilateral orchidectomy with other modalities in the treatment of advanced prostate cancer. This was a retrospective study of nineteen (19) patients who had bilateral orchidectomy in the year 2019. Information retrieved from their case notes included biodata, history and physical examination findings with results of laboratory investigations. Information on preoperative treatments was also documented. Informed consent was taken from patients before surgery and post operative complications were documented. Cost of surgery was compared with cost of the other treatment modalities for prostate cancer. There were 19 patients with a mean age of  $66.89 \pm 8.65$  years. Majority of the patients (47.4%) were in their 8<sup>th</sup> decade of life. More than 50% of patients had Gleason Score of 9 and above. Anaesthesia was achieved using local infiltration with 1% xylocaine for 90% of the patients, while others received subarachnoid block. Post operative complication was low. Bilateral orchidectomy for advanced prostate cancer is simple, safe and cost effective compared to other modalities of treatment.*

**Keywords:** Cost-effectiveness, advanced prostate cancer, bilateral orchidectomy, medical orchidectomy

### INTRODUCTION

Prostate Cancer (PCA) has been recorded as the commonest malignancy of the male Urogenital tract.<sup>1</sup> Huggins *et al.* documented that both normal and Prostate cancer cell growth depends on serum testosterone secreted by the Leydig cells of the testes.<sup>2,3</sup> They also reported that the easiest way to achieve hormonal blockade as a treatment option for advanced PCA is bilateral orchidectomy. This procedure was somehow abandoned with the emergence of medical castration using luteinizing hormone releasing hormone analogue [LHRH(a)] for quality-of-life reasons in respect of an empty scrotal sac.<sup>4</sup> Where it is indicated as in advanced PCA with documented or imminent spinal cord compression, severe cancer pain and with poor compliance to tablets or injections, bilateral orchidectomy is the

treatment of choice. Hormonal blockade can also be achieved with other treatment modalities including LHRH(a), oestrogen compounds, anti-androgens (steroidal and non-steroidal) etc, but none has shown better effectiveness with fewer side effects than surgical castration.<sup>5</sup> Schmitt *et al* noted that bilateral orchidectomy is superior to even maximal androgen blockade (MAB) or to LHRH analogue alone.<sup>6</sup> It is a simple, safe, cost-effective and permanent procedure, unlike other therapies that require daily ingestion of drugs or periodic injections with cumulative costs.

In this study, we aimed at evaluating the cost of bilateral orchidectomy, comparing it with other treatment modalities for advanced PCA in order to demonstrate its cost-effectiveness.

### MATERIALS AND METHODS

This was a retrospective study of 19 patients who underwent bilateral orchidectomy in the year 2019. A search was conducted in the operating room (OR) registers for names and hospital numbers of

Urology Firm, Department of Surgery, University of Uyo Teaching Hospital, Uyo, Akwa Ibom State, Nigeria.

\*Corresponding author: [elijah\\_udoh@yahoo.com](mailto:elijah_udoh@yahoo.com)

Date manuscript was received: 21/3/2022

Date manuscript was accepted: 2/7/2022

these patients. Subsequently, patient's case notes were retrieved from the records department. Information obtained was biodata, history and physical examination findings. Laboratory investigation results included full blood count, renal function test, Prostate Specific Antigen (PSA), Urinalysis and urine culture. Prostate biopsy result of each patient was also documented.

Preoperative treatment regimen were anti-androgens (Flutamide and bicalutamide), medical castration with LHRH(a) and combination therapy with anti-androgen and LHRH(a). How long each therapy lasted before surgery was noted. Normally, informed consent is usually taken from all patients before surgery with emphasis on the benefits of the procedure as the best option vis-a-vis their stage of disease and the attendant complications which may include, but not limited to, loss of libido and erectile dysfunction, loss of muscle mass, loss of physical energy and hot flushes. Type of anaesthesia was also discussed, and patients were given the option to choose. Post operative care consisted of scrotal support, antibiotics and analgesics. Indications for admission were due to other complications not necessarily from the procedure. Cost of the procedure and cost of other treatment modalities were also recorded. Post operative complications were documented as this may also affect the cost.

Collated data were inputted into statistical package for social sciences (SPSS) version 20.0 and analyzed. Mean values were obtained for continuous variables while frequency table was constructed for categorical variables. Costs of treatment were compared.

## RESULTS

Nineteen (19) patients with a mean age of  $66.69 \pm 8.65$  years were studied (Table 1). Most of them (47.4%) were in their 8<sup>th</sup> decade of life (Table 2). More than 50% of the men had three (3) or more complications of PCA which were bone metastasis with low back pain, paraplegia, metastasis to the liver with jaundice and cough from Pulmonary metastasis. Mean serum PSA was  $71.64 \pm 61.78$  ng/ml. Gleason Score of 9 and above (WHO ISUP grade group 5) were noted in more than 50% of patients (Table 3). Mean Gleason score was  $8.11 \pm 1.10$ . About 80% of them (Table 4) had aggressive disease defined as WHO ISUP grade group 3 to 5 and 31.6% had documented clinical and imaging evidence of osseous metastasis to the lumbo-sacral spine. Initial treatment was mostly with flutamide. Local anaesthesia with 10mls of 1% Xylocaine was used for 90% of patients while 10% of them received subarachnoid block. Post operatively, 25% of them were admitted while 75% were day cases. Wound infection or surgical site infection defined as infection that occurs at or near the surgical incision within 30 days following the procedure was noted in 6(31.6%) patients (Table 5). Isolated organism was consistently *Staphylococcus aureus*. Cost of bilateral orchidectomy was equivalent to a single dose of LHRH(a) and a three-month oral dose of flutamide (Fig.1). The total cost of bilateral orchidectomy including post operative medications was about fifty thousand Naira while a month injection of LHRH(a) or a 3-monthly dose of Flutamide was about forty-five thousand Naira.

Table 1: Baseline Characteristics of Patients

Variable	Mean $\pm$ SD	Minimum	Maximum
Age (years)	$66.89 \pm 8.65$	47	81
Duration of LUTS( in months)	$8.53 \pm 5.49$	1	24
Serum PSA	$71.64 \pm 61.78$	6.50	281.00
P <sub>1</sub>	$3.79 \pm 0.91$	2	5
P <sub>2</sub>	$4.32 \pm 0.74$	3	5
Gleason Score	$8.11 \pm 1.10$	5	9

[P<sub>1</sub> = Most predominant grade, P<sub>2</sub> = Next most predominant grade]

Table 2: Age Categorization in Decades

Variables	Frequency(n)	Percentages (%)	Cumulative (%)
Age in decades			
40 -49	1	5.3	5.3
50 -59	2	10.5	15.8
60 -69	6	31.6	47.4
70 -79	9	47.4	94.7
80 -89	1	5.3	100.0
Total	19	100.0	

Table 3: Who ISUP Grading/Score

Gleason score	Frequency (n)	Percentage %	Cumulative (%)
<6	2	10.5	10.5
3 + 4 = 7	3	15.8	26.3
4 + 3 =7	4	21.1	47.4
4 + 4 = 8	0	0.0	47.4
9 and above	10	52.6	100.0
Total	19	100.0	

Table 4: Level of Aggressiveness

Groups	Frequency(n)	Percentages (%)	Cumulative (%)
1& 2	4	21.1	21.1
3 and above	15	78.9	100.0
Total	19	100.0	

[Groups 1&2 = Non-aggressive, 3 and above = aggressive tumours

Table 5: Complications of Surgery

Complications	Frequency(n)	Percentages (%)	Cumulative (%)
Nil	13	68.4	68.4
Wound haematoma	0	0.0	68.4
Wound infection	6	31.6	100.0
Total	19	100.0	

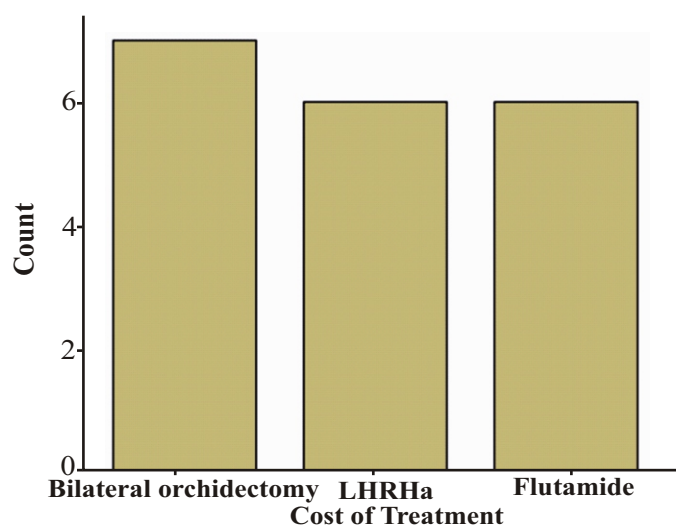


Figure 1: Comparing Cost of Treatment Between bilateral Orchidectomy, Lhrha (A Month's Dose) And Flutamide (3-Month's Dose)

## DISCUSSION

Treatment of prostate cancer depends on the stage of the disease. Those presenting with early disease are usually offered curative therapies such as radical Prostatectomy or radical Radiotherapy. With advanced cancers as is commonly seen among our patients, only palliative treatment in the form of LHRH(a) and antagonists, bilateral orchidectomy, oestrogen compounds and antiandrogens become the mainstay of therapy. However, not all patients with advanced disease can be safely treated with hormonal therapy because of adverse cardiac and cardiovascular issues common in this age bracket as in treatment with oestrogen compounds. Patients are usually counseled on the options of treatment after diagnosis is made and studies have noted that about 50% of patients choose bilateral orchidectomy for reasons of cost and convenience.<sup>7</sup> It is a simple, safe procedure that achieves castrate level of testosterone within 3 to 12 hours as against 3 to 4 weeks after the first dose of LHRH(a) injection.<sup>8,9</sup> Again LHRH(a) has been shown to be ineffective in completely eliminating testosterone in patients, but in one study bilateral orchidectomy completely got rid of testicular androgen produced by the Leydig cells.<sup>10,11</sup> In the context of advanced disease, testosterone suppression or elimination is central in the treatment and for reasons of suboptimal control as seen in patients receiving other therapies, bilateral orchidectomy remains a superior option. Despite the advantages of bilateral orchidectomy, patients' concerns about the psychological stress of an empty scrotal sac, loss of male identity and poor body image should be viewed seriously. This may affect choice of treatment.<sup>12</sup> Removal of both testes is permanent. There must be other indications for hormonal blockade especially where intermittent treatment is anticipated or in patients that reject bilateral orchidectomy.

We evaluated the cost of bilateral orchidectomy in patients that underwent this procedure in the year 2019 and made a comparison with the cost of other treatment modalities (Fig.1). The mean age of patients was  $66.89 \pm 8.65$  years (Table 1). Most of them

(47.4%) were in their 8<sup>th</sup> decade of life (Table 2). The least of them in number was observed in the 5<sup>th</sup> decade of life probably due to disease rarity in people within this age bracket and unwillingness to choose this option.

Gleason Score of 9 and above were documented in more than 50% and 78.9% had aggressive disease. This supported the choice of bilateral orchidectomy being a better option of treatment in this scenario. All patients presented with complications of Prostate cancer and more than half of the men had 3 or more complications which were bone metastasis with low back pain, paraplegia, metastasis to the liver with jaundice and cough from pulmonary metastasis. It is not surprising as patients presentation for care in many Sub-Saharan African centres is usually late.<sup>13,14</sup> Thirteen (68.4%) patients received Flutamide before surgery. We routinely commence treatment with Flutamide irrespective of any other options chosen later by the patients. This is to avoid the flare phenomenon in patients who will opt for LHRH(a) and delayed treatment for those who may later choose bilateral orchidectomy. Only 2(10.5%) patients were pre-treatment naïve who needed urgent castration for imminent spinal cord compression. Majority (89.5%) of them had local infiltration for anaesthesia and 10.5% opted for spinal anaesthesia. Fourteen (73.7%) patients were discharged same day while 5(26.3%) of them were admitted not necessarily because of the surgery but needed stabilization of their complications. It is generally known that bilateral orchidectomy is a day case procedure. Complication rate was moderately low (31.6%), mostly wound infection that healed with sitz bath and daily dressing with honey. We did not observe wound haematoma probably due to bandaging and scrotal support that all patients had for 48 to 72 hours. This probably must have contributed to low surgical complication rate as haematoma formation also predisposes to wound infection.

The issues of cost of therapy should be viewed as an integral component in



decision making. No matter how golden a set of therapy is, if patients cannot afford, it will amount to a wasted effort. Bilateral orchidectomy is cheap, safe with fewer side effects and this should be emphasized by Urologists to patients during choice of therapy. Bonzani *et al.* reported that the cost of medical therapy was higher than bilateral castration in patients with advanced disease.<sup>15</sup> Wright *et al.* also noted a decrease in medical therapy in favour of surgical castration for reasons of cost.<sup>16</sup> Even in patients admitted after bilateral orchidectomy, the hospital bill was also noted to be lower than an average cost of LHRH agonist therapy in one study.<sup>17</sup>

In this study, cost of bilateral orchidectomy was equivalent to the cost of a single dose of LHRH agonist and a three-month dose of Flutamide. This is really expensive considering the fact that medical castration is received monthly and Flutamide medication is taken daily, both for a lifetime, whereas, surgical castration is done once and permanent. Paula *et al.*<sup>18</sup> noted in 2003 that a single dose of LHRH agonist in Brazil was 1.6 times higher than the surgical procedure. Costs of anti-androgens (Flutamide or Bicalutamide) were also noted to be equal to bilateral orchidectomy after 3 months of medications. These drugs are taken for life unless otherwise indicated in lieu of disease progression or patient's preference.

## CONCLUSION

Bilateral orchidectomy is a simple, safe and cost-effective procedure in the treatment of advanced PCA. This type of treatment however precludes intermittent androgen therapy whereas other modalities are useful here. We suggest that Urologists should incorporate cost of therapy during counseling of patients for Prostate cancer treatment options and as a matter of cost consideration, propose surgical castration especially in advanced diseases.

## REFERENCES

1. Borre M, Nerstrom B, Overgaard J. The natural history of prostate carcinoma based on a Danish population treated with no intent of cure. *Cancer* 1997;80:917-28.
2. Huggins C, Hodges CV. Studies on prostate cancer: the effect of castration of estrogen and of androgen injection on serum phosphatases in metastatic carcinoma of the prostate. *Cancer Res* 1941;1:293-7.
3. Oefelein MG, Resnick MI. Effective testosterone suppression for patients with prostate cancer: Is there a best castration? *Urology* 2003;62:2007.
4. Melton LJ 3<sup>rd</sup>, Althman KI, Achenbach SJ, O' Fallon WM, Zineke H. Decline in bilateral orchidectomy for prostate cancer in Olmsted County, Minnesota, 1956-2000. *Mayo Clin Proc* 2001;76:1199-203.
5. Malkowics SB. The roles of Diethylstilbestrol in the treatment of prostate cancer. *Urology* 2001;58:108-13.
6. Schmitt B, Witt TJ. Combined androgen blockade with non-steroidal anti-androgens for advanced prostate cancer: a systematic review. *Urology* 2001;57:727-32.
7. Chadwick DJ, Gillat DA, Gingell JC. Medical or Surgical Orchidectomy: The patient's choice. *BMJ* 1991;302:572.
8. Maatman TJ, Gupta MK, Montie JE. Effectiveness of castration versus intravenous estrogen therapy in producing rapid endocrine control of metastatic cancer of the prostate. *The Journal of Urology* 1985;133:620-1.
9. Limonta P, Marelli MM, Moretti RM. LHRH analogues as anticancer agents: Pituitary and extra-pituitary sites of action. Expert opinion on investigational drugs 2001;10:709-20.
10. Kawakami J, Morales A. Clinical Significance of Suboptimal hormonal levels in men with prostate cancer treated with LHRH agonists. *Can Urol Assoc J.* 2013;7:E226-30.

11. Zaitzu M, Yamanoi M, Mikami K, Takeshina Y, Okamoto N, Imao S *et al.* Surgical castration in hormonerefractory metastatic prostate cancer patients can be an alternative for medical castration. *Adv Urol* 2012;979154.
12. Zhang XZ, Donovan MP, Williams BT, Mohler JL. Comparison of sub-capsular and total orchidectomy for treatment of metastatic prostate cancer. *Urology* 1996; 47:402-4.
13. Ajape AA, Ibrahim KO, Fakeye JA, Abiola OO. An overview of cancer of the prostate diagnosis and management in Nigeria. The experience in a Nigerian tertiary hospital. *Ann Afr Med* 2010;9:113-7.
14. Bowa K. An overview of the diagnosis and management of prostate cancer in Nigeria: Experience from a North-Central State of Nigeria. *Ann Afr Med* 2010; 9:111-2.
15. Bonzani RA, Stricker HJ, Peabody JO, Menon M. Cost comparison of orchiectomy and leuprolide in metastatic prostate cancer. *J. Urol* 1998;160:2446-9.
16. Weight CJ, Klein EA, Jones JS. Androgen deprivation falls as orchiectomy rates rises after changes in reimbursement in the US medicare population. *Cancer* 2008; 112:2195-201.
17. Varenhorst E, Carlsson P, Pedersen K. Clinical and economic considerations in the treatment of Prostate cancer. *Pharmacoeconomics* 1994;6:127-41.
18. Paula AAP, Piccelli HRS, Pinto NP, Teles AG, Franqueiro AG, Maltez ARL *et al.* Economical impact of orchidectomy for advanced prostate cancer. *Int Braz. J. Urol* 2003;29:1677- 84.